

V súvislosti s týmto podujatím nemám žiaden  
konflikt záujmov.

MUDr.Tomáš Sedláček

Medicyt, s.r.o.

Bioptické a cytologické laboratorium Trenčín

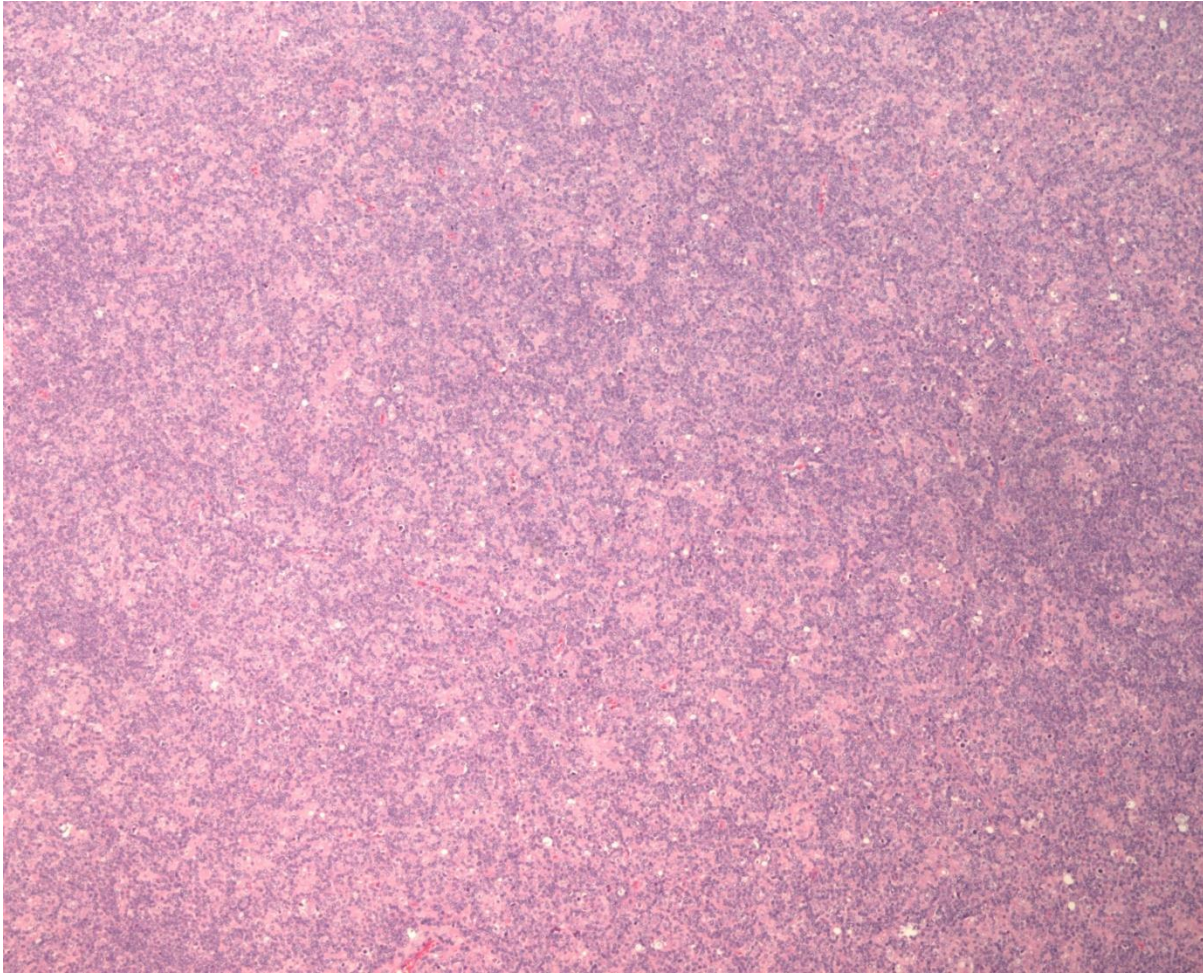
# Prípad SD-IAP č.720



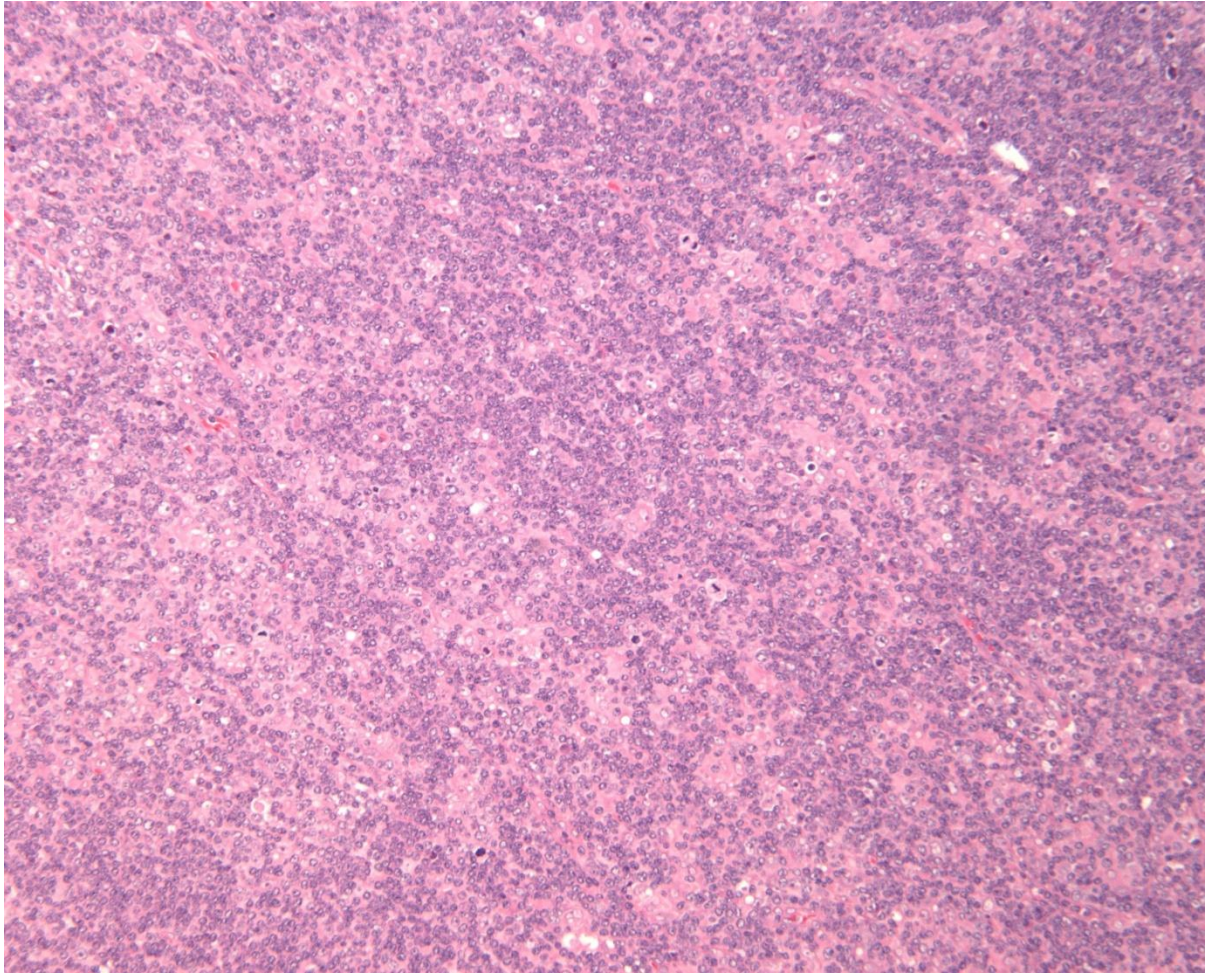
# Klinické údaje

- 42-ročný muž
- infektológ ➡ supraklavikulárna LU l.dx. (5 cm)
- generalizovaná lymfadenopatia
- **CT** + LAP mediastinum, panva + pľúca l.dx.
- lymfatická uzlina 4x3x3 cm

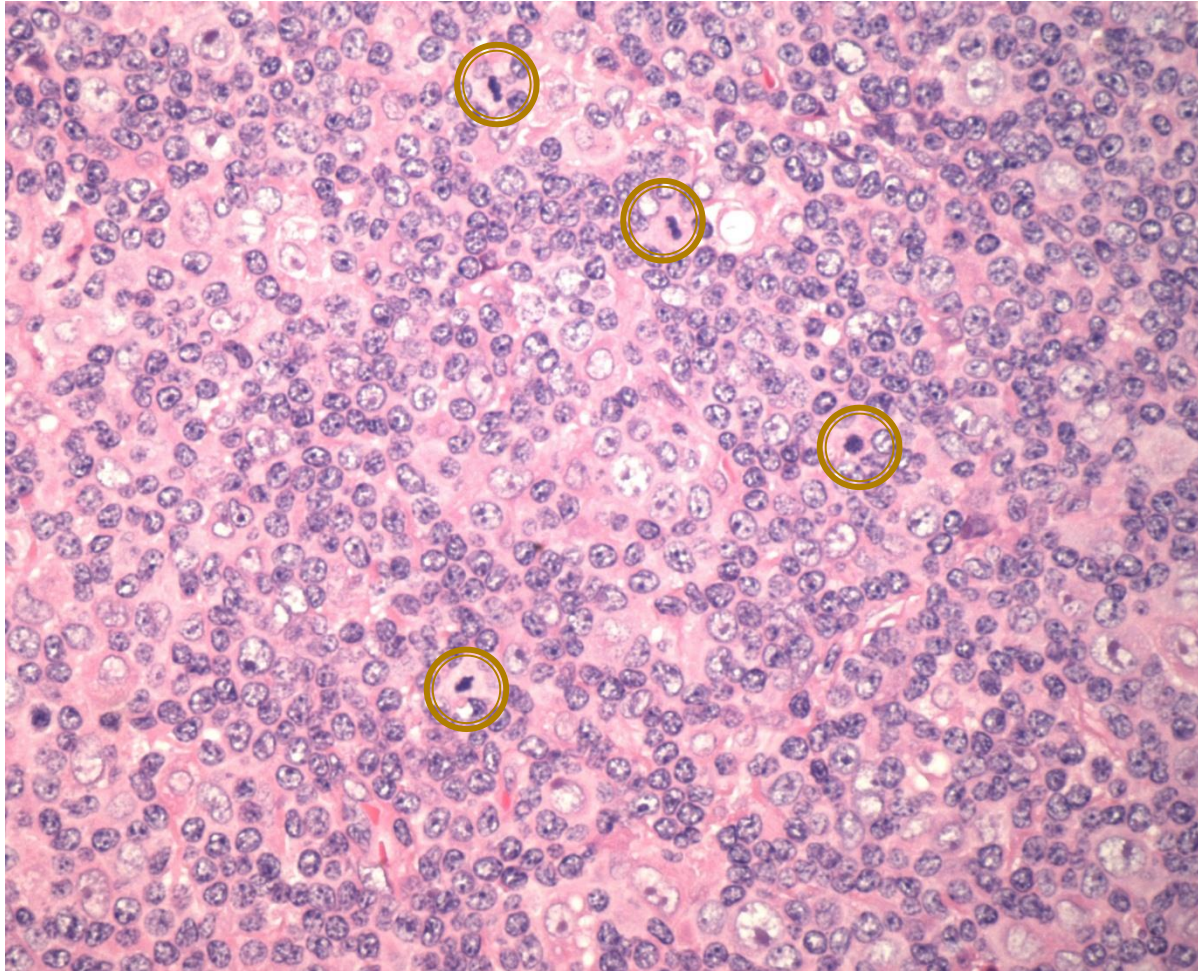
# Architektonika



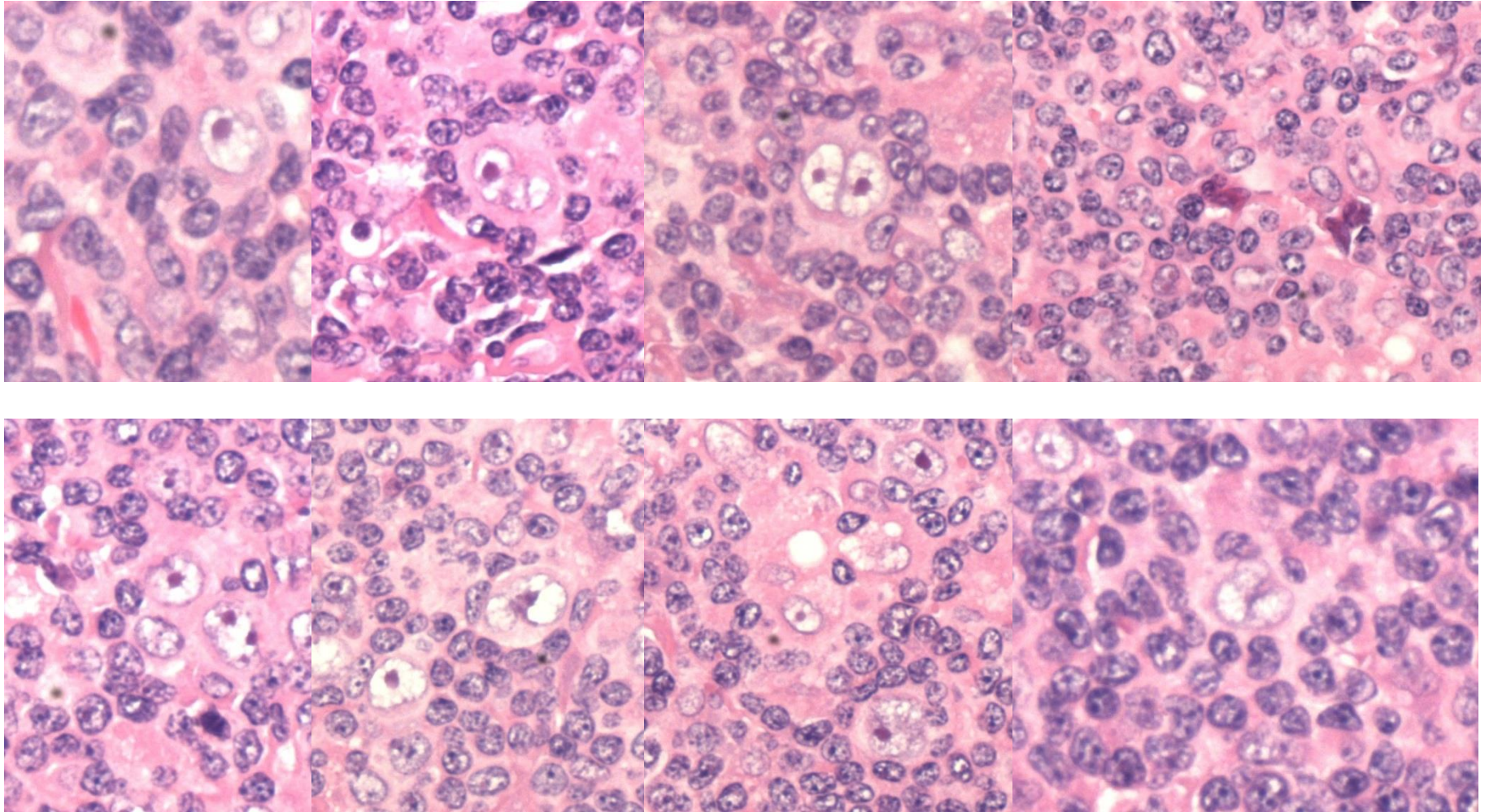
# Architektonika



# Bunková populácia



# Bunková populácia








# IHC - architektonika

**PAX-5**



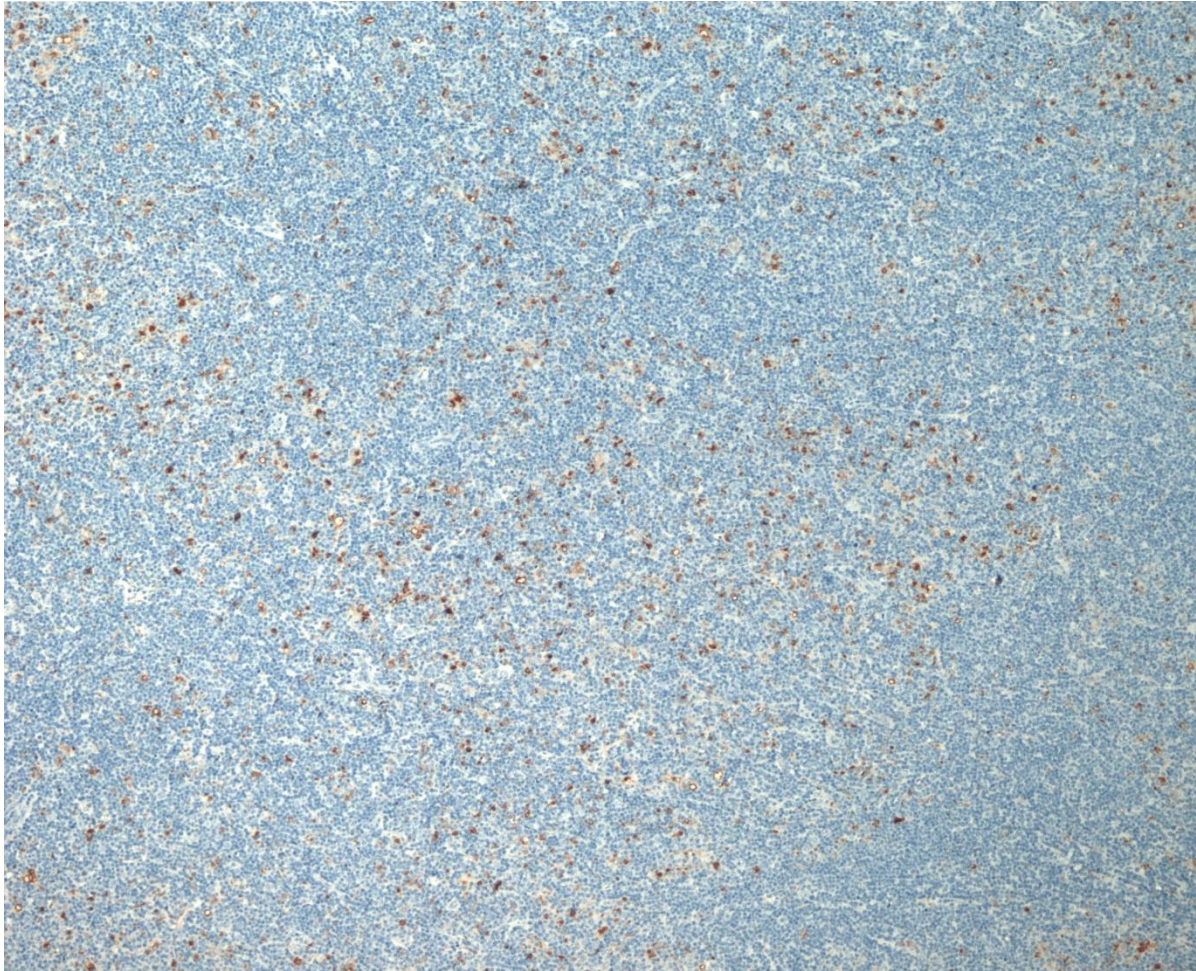
# IHC - architektonika

**CD5**



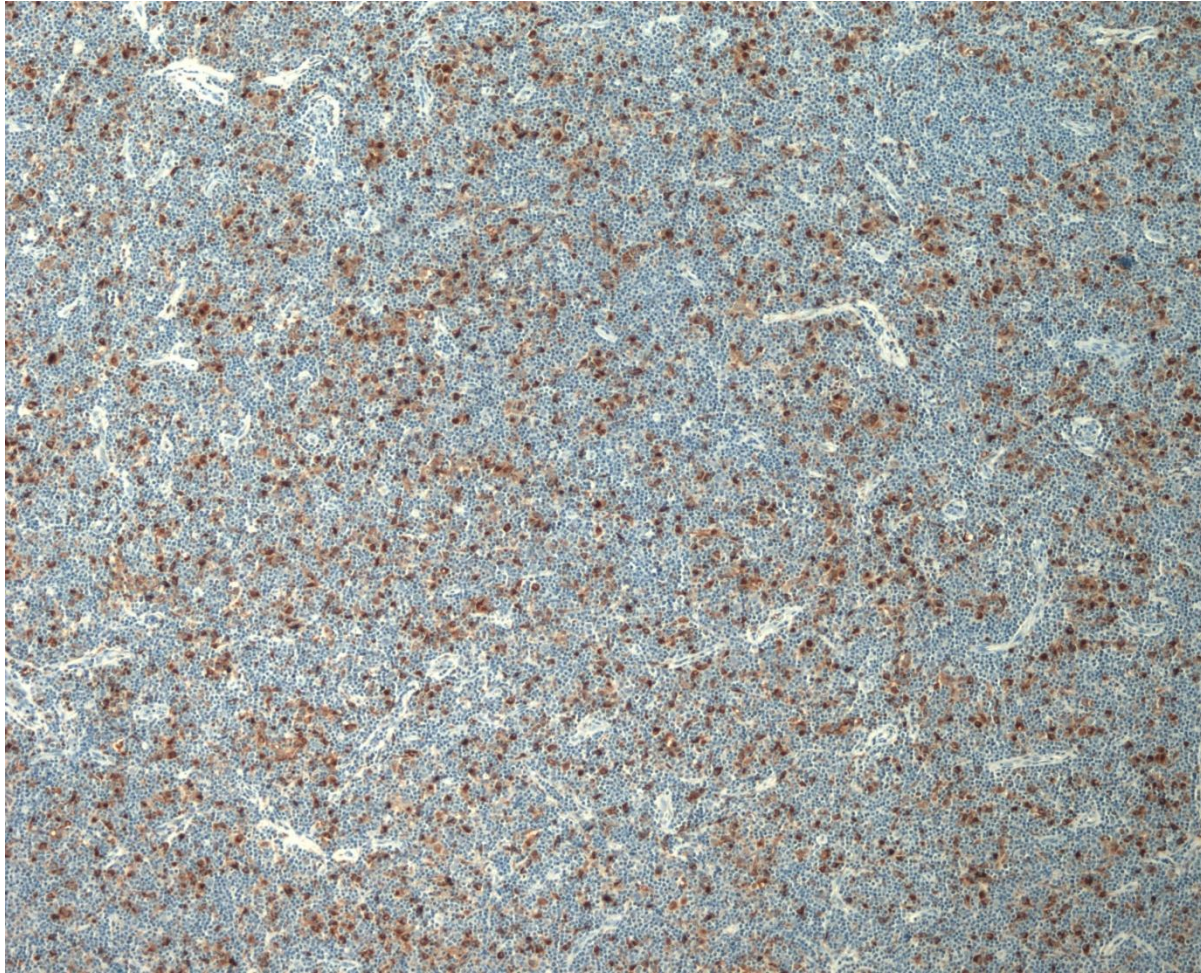
# IHC - architektonika

**CD68**



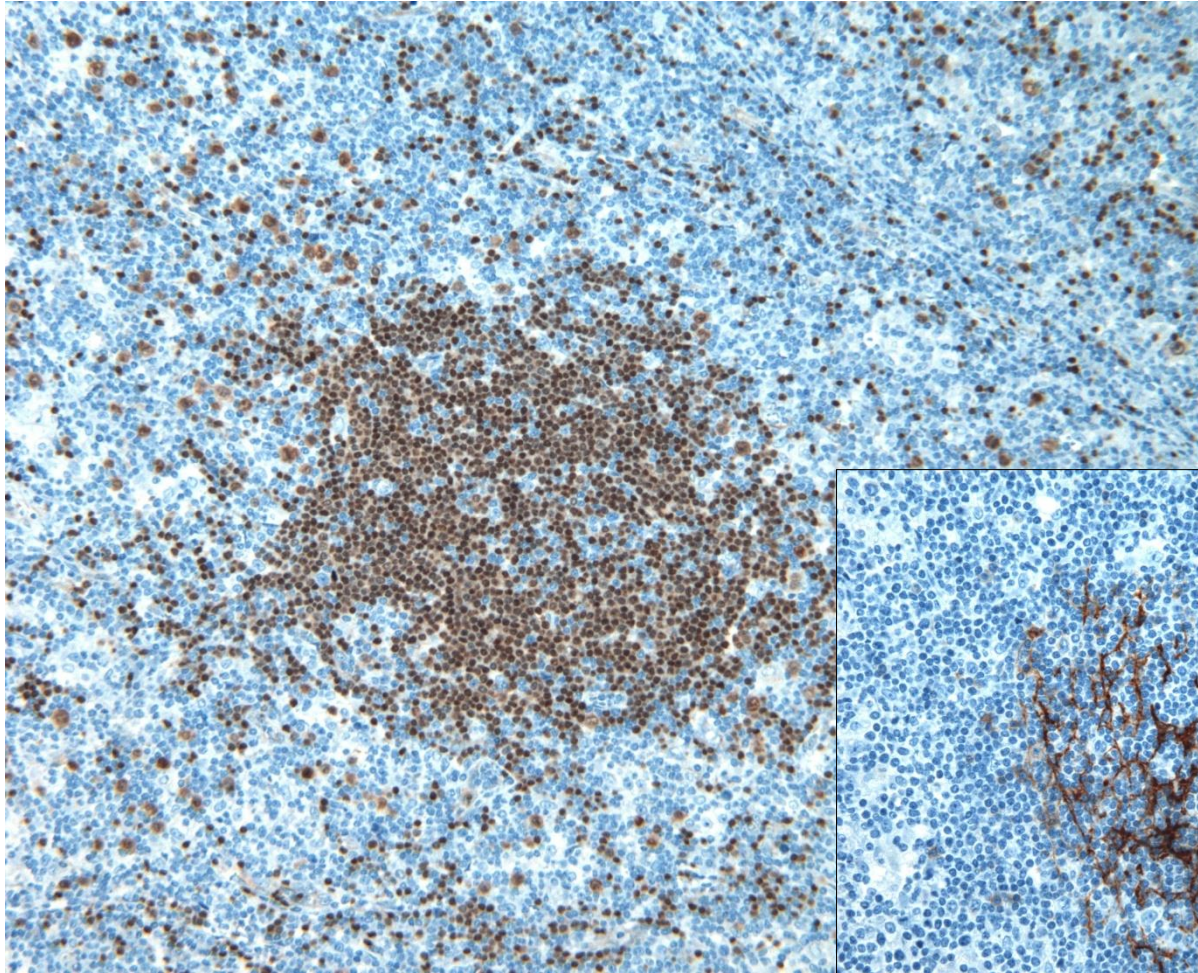
# IHC - architektonika

**CD68**

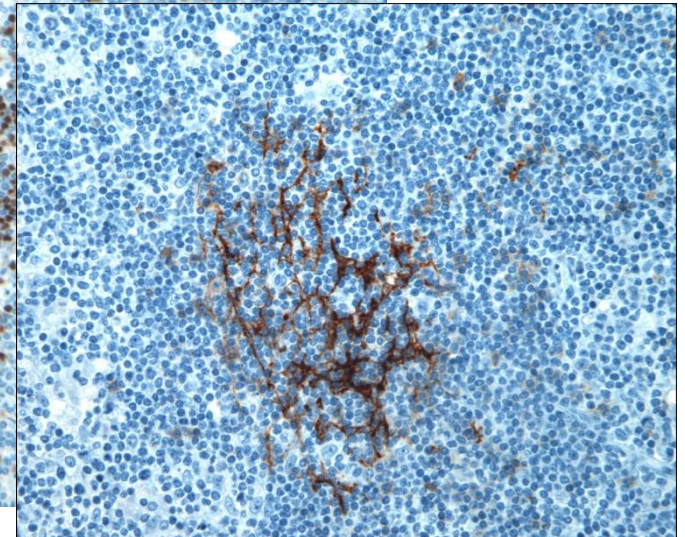


# IHC - architektonika

**PAX-5**

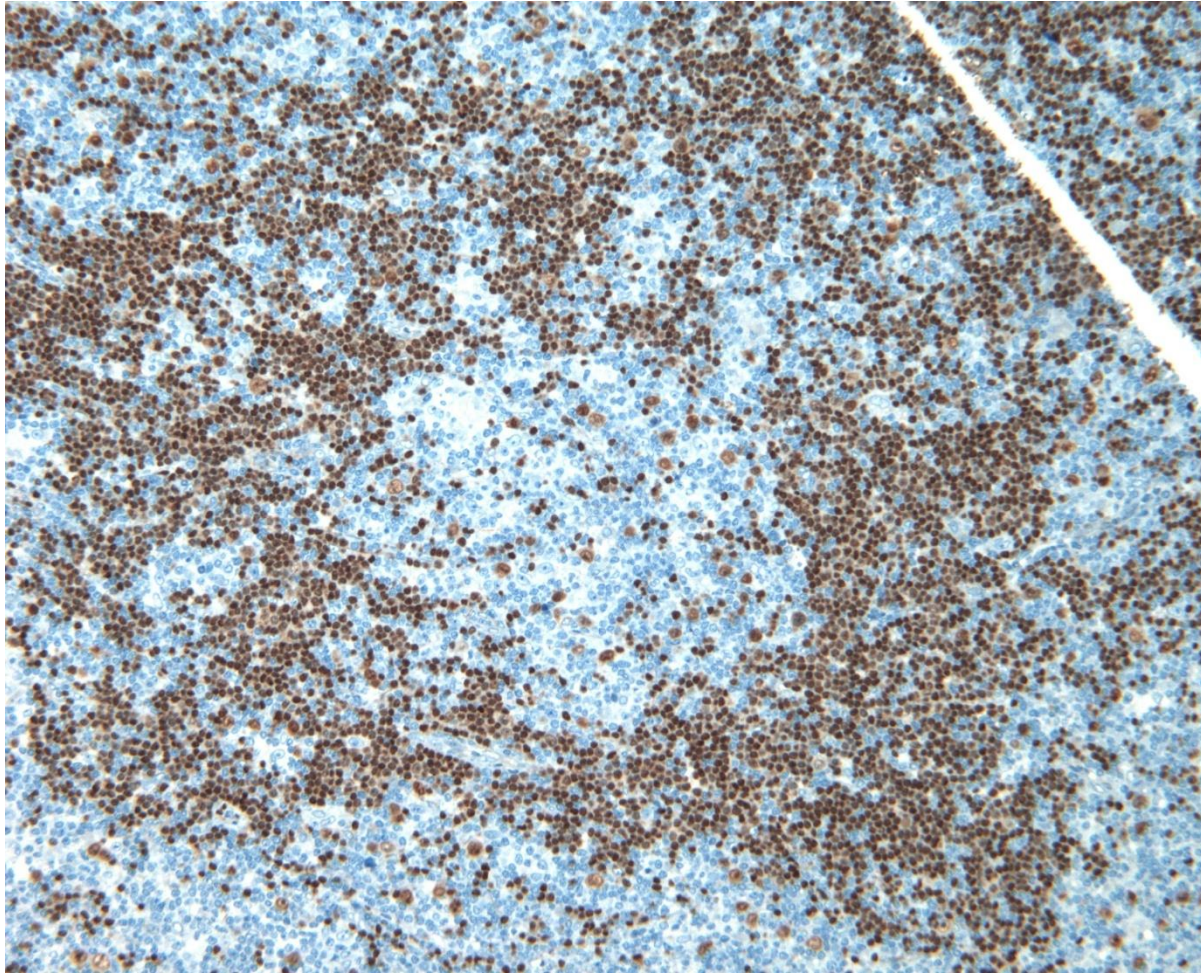


**CD23**



# IHC - architektonika

**PAX-5**




# IHC - architektonika

**PAX-5**



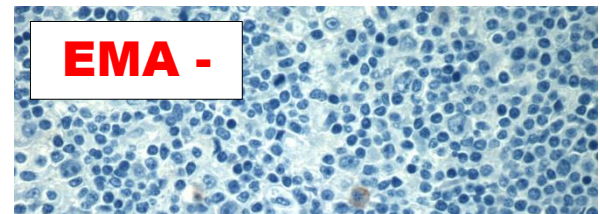
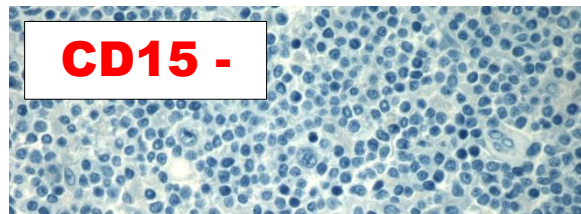
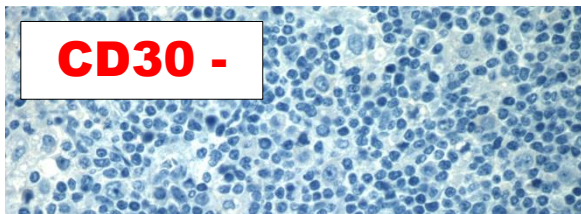
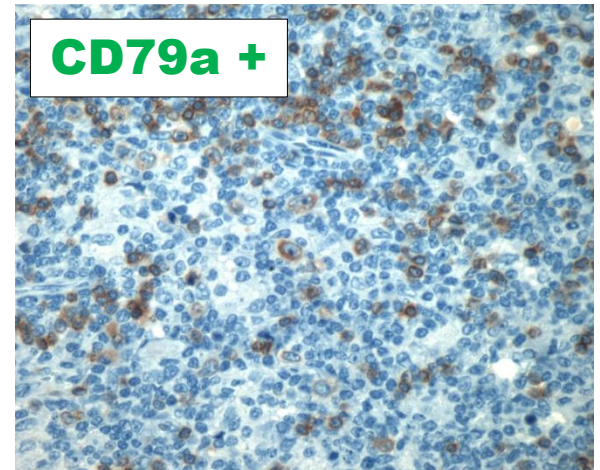
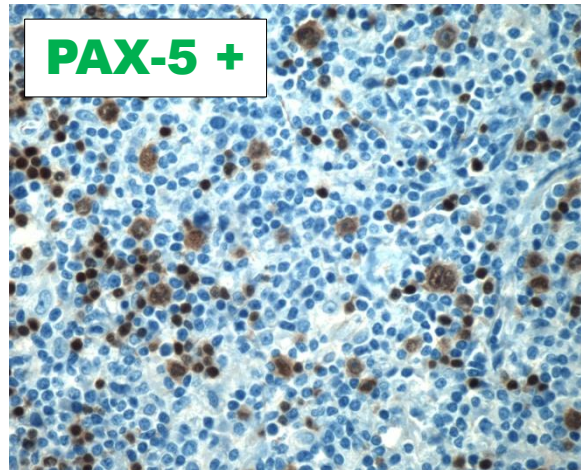
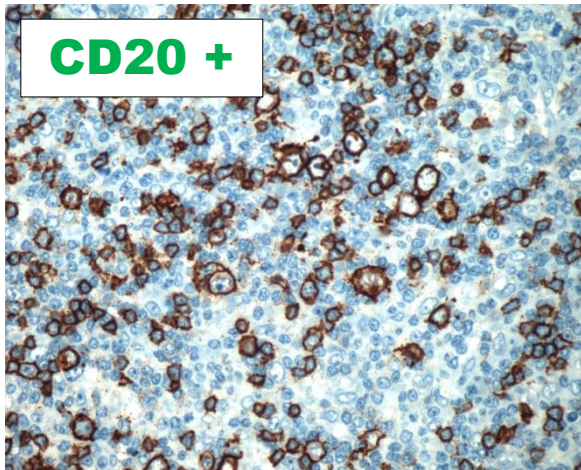
# IHC - architektonika

**CD20**



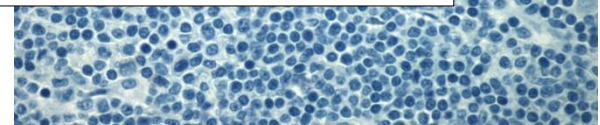
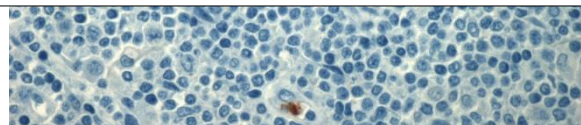
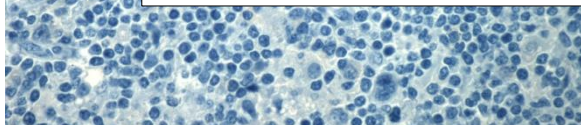


# Imunoprofil nádorových buniek




**EBV EBER(ISH) -**  
**ALK1 -**

Prof. MUDr. Ludmila Boudová, PhD.



# Rozmiestnenie nádorových buniek

**CD20**





**Nodular  
lymphocyte predominant  
Hodgkin lymphoma**

**with variant features**

# NLPHL

## Hodgkin lymphomas

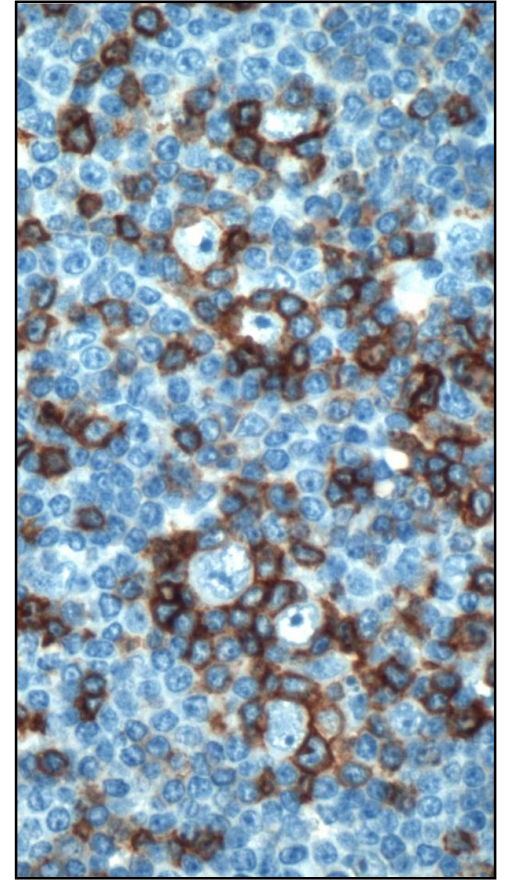
- **Nodular lymphocyte predominant Hodgkin lymphoma**
- Classic Hodgkin lymphoma
  - Nodular sclerosis classic Hodgkin lymphoma
  - Lymphocyte-rich classic Hodgkin lymphoma
  - Mixed-cellularity classic Hodgkin lymphoma
  - Lymphocyte depleted classic Hodgkin lymphoma

# NLPHL

## B-bunková neoplázia

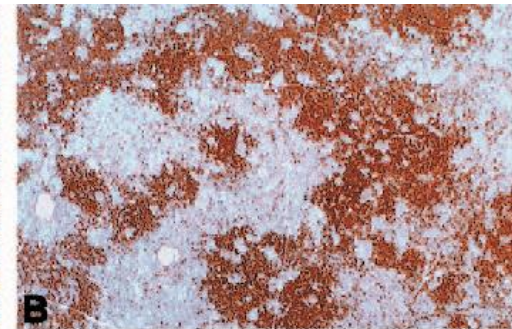
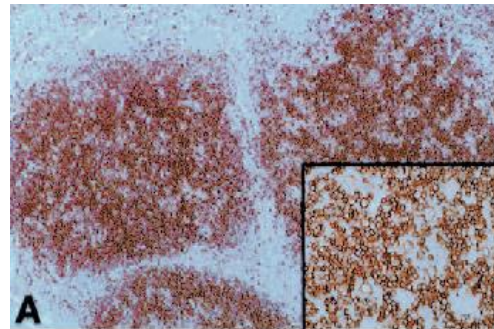
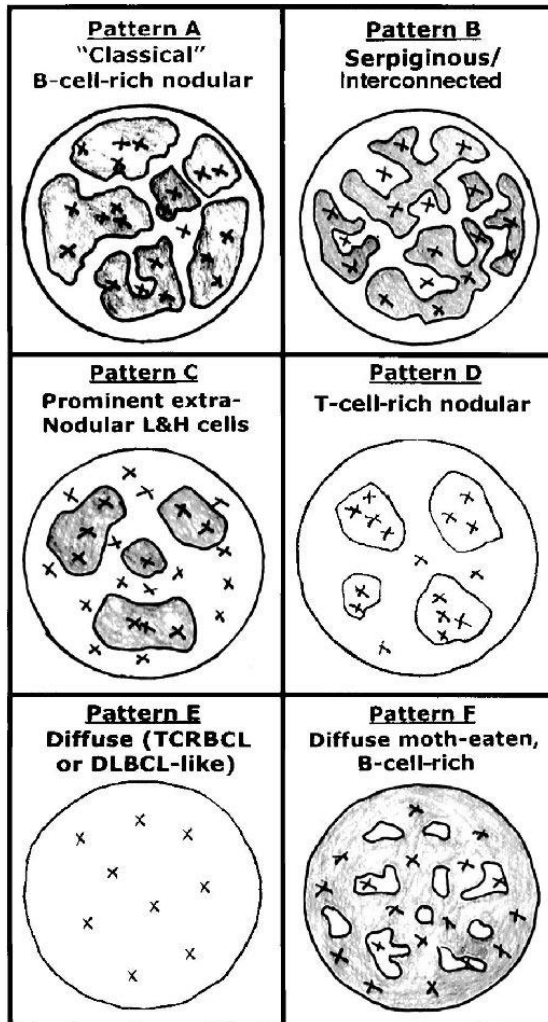
- s nodulárnou /a difúznou proliferáciou
- lymphocyte predominant (LP, L&H), popcorn cells
- lemované PD1/CD279+ T bunkami

- mladý ľudia, muži (30-50 ročný)
- lokalizovaná periférna LAP (stage I, II) 80%
- rastúce pomaly, s relapsami
- odpovedajúce na liečbu
- 10 – ročné prežívanie viac ako 80%

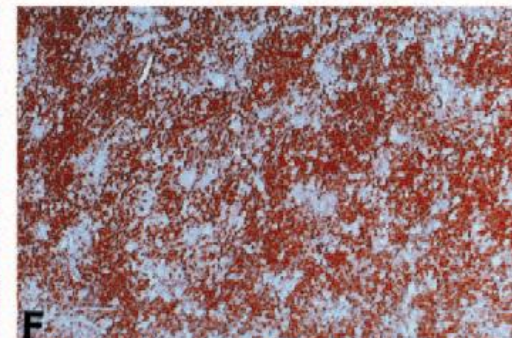
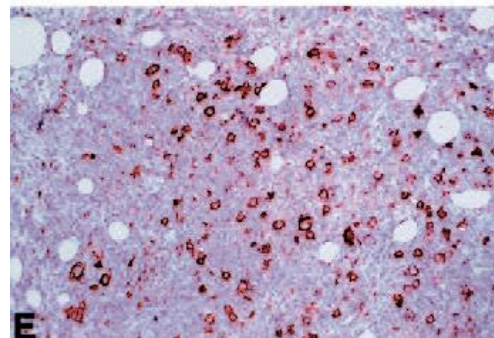
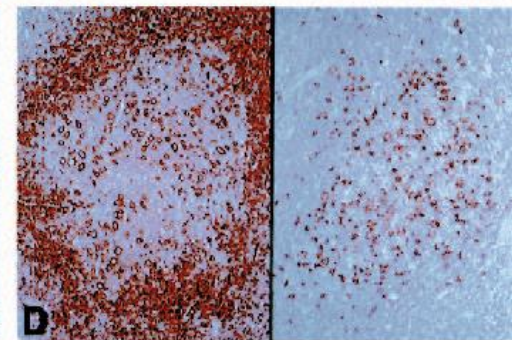
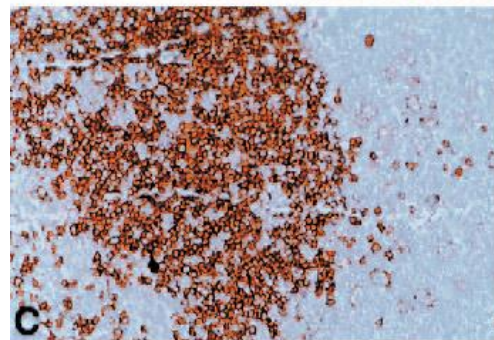


# Variant Patterns of NLPHL

Fan Z, Am J Surg Pathol (2003) / 137



**CD20**



# NLPHL with T-cell-rich nodules / 235

Nodular lymphocyte-predominant Hodgkin lymphoma with nodules resembling T-cell/histiocyte-rich B-cell lymphoma: differential diagnosis between nodular lymphocyte-predominant Hodgkin lymphoma and T-cell/histiocyte-rich B-cell lymphoma

**Ludmila Boudova**, Emina Torlakovic, Jan Delabie, Peter Reimer, Beate Pfistner, Sabine Wiedenmann, Volker Diehl, Hans-Konrad Muller-Hermelink, and Thomas Rudiger

BLOOD © 2003 by The American Society of Hematology

Diagnostic criteria

Biologic continuum

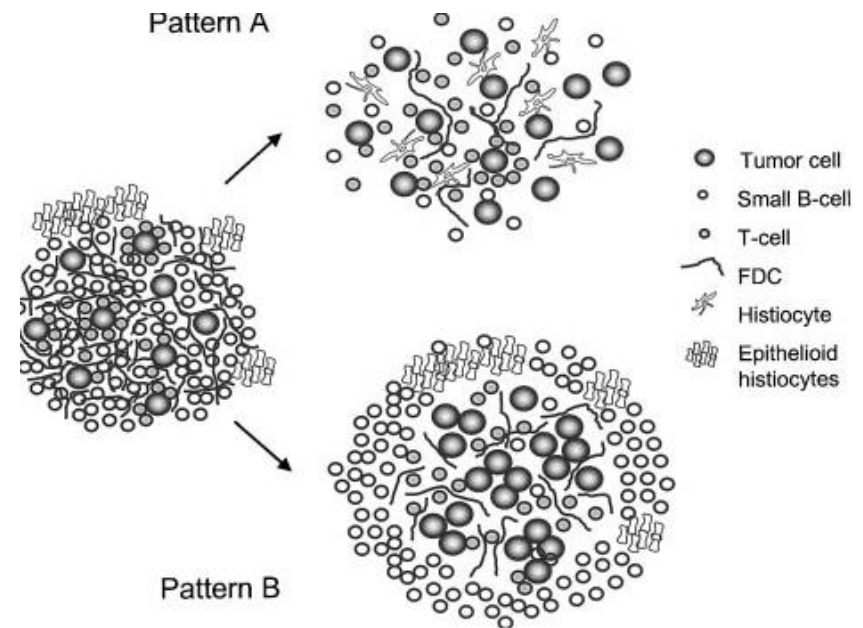


Figure 3. Schematic depiction of the 2 patterns of NLPHL with T-cell/histiocyte-rich nodules as possible pathways of morphologic progression of NLPHL.



# Variant histology in NLPHL (25%) / 423

The prognostic impact of variant histology in nodular lymphocyte-predominant Hodgkin lymphoma: a report from the German Hodgkin Study Group (GHSg)

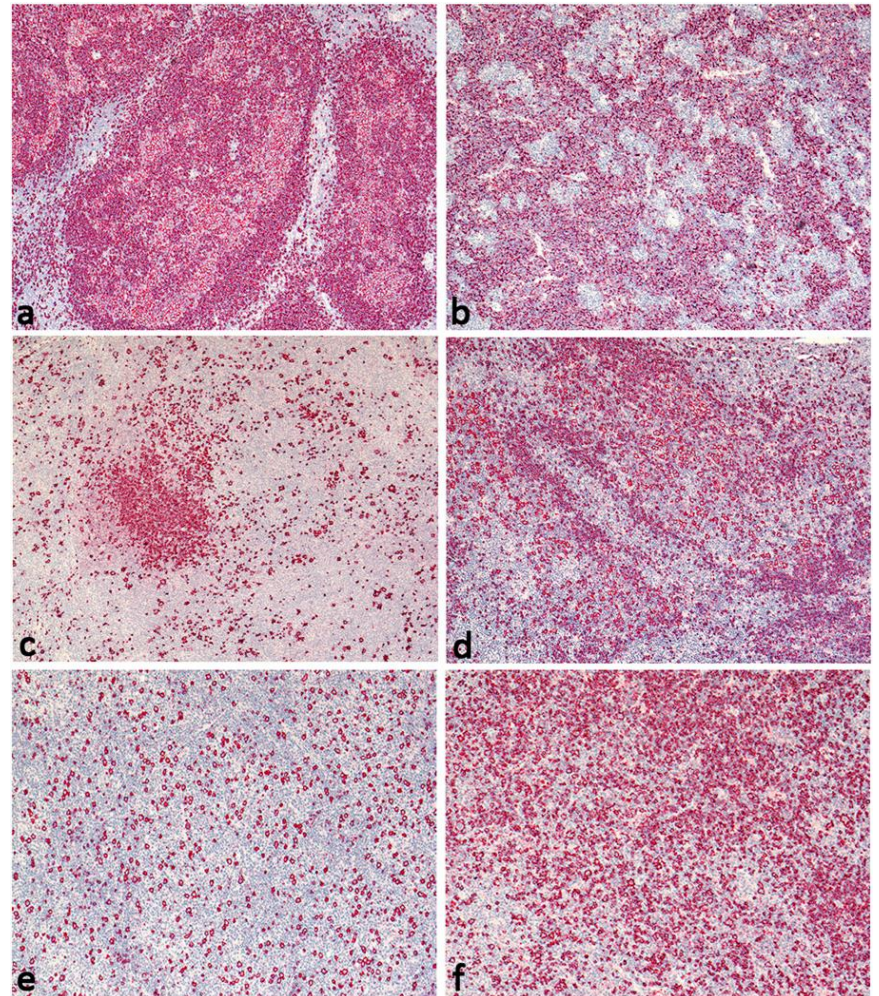
Sylvia Hartmann et al

BLOOD © 2013 by The American Society of Hematology

**LP cells outside** the B-cell nodules  
(altered homing)

or

**B-cell depletion** of the microenvironment



# Diferenciálna diagnostika

Classic  
Hodgkin lymphoma  
lymphocyte-rich  
(CHL)

**NODULAR**

**DIFFUSE**

T-cell/histiocyte-rich  
large B-cell lymphoma  
(THRLBCL)

EBV-positive diffuse  
large B-cell lymphoma,  
NOS (EBV+ DLBCL, NOS)

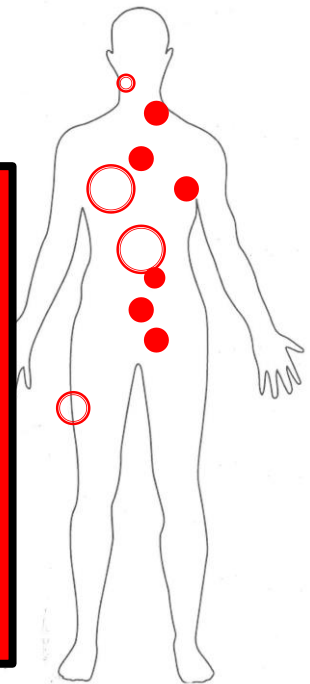
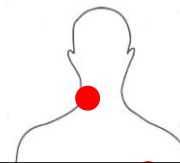

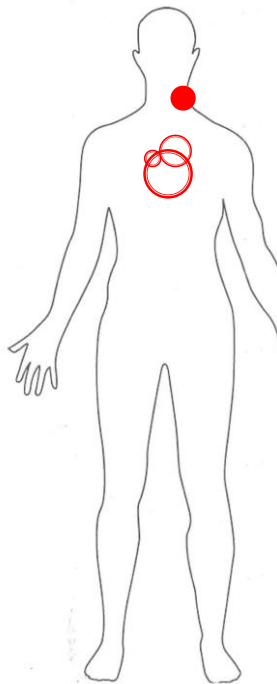
# Diferenciálna diagnostika

CHL

NLPHL

THRLBCL

EBV+  
DLBCL  
NOS



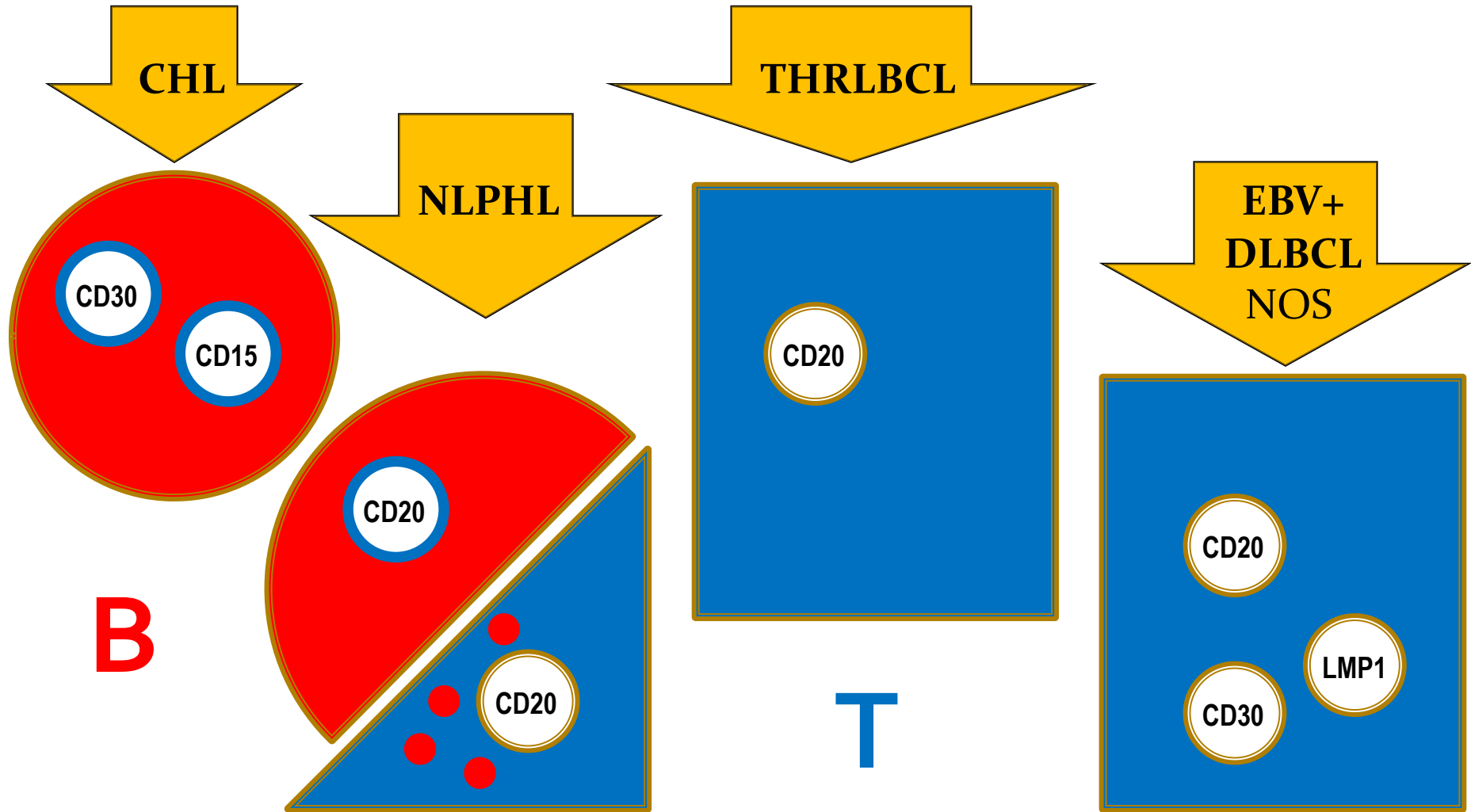
## **<sup>18</sup>FDG PET/CT:**

- hypermetabolická LAP na **krku vpravo**
- a v hornom, resp.zadnom **mediastine**
- infradiafragmaticky LU, orgány a skelet negat.

## **Trepanobiopsia KD:**

- negatívna.

# Diferenciálna diagnostika



# Diferenciálna diagnostika

CHL

NLPHL

THRLBCL

EBV+  
DLBCL  
NOS

Polychemotherapy

Active surveillance  
Radiotherapy  
verzus  
Chemotherapy

Chemotherapy

Chemotherapy

**ABVD**

**BEACOPP**

+ Radiotherapy

**CD30**

brentuximab  
vedotin

(Refractory)

(Remisia 60%)

**CHOP**

Fanale et al, 2017 / NCCN

**CD20**

Rituximab  
(R-CHOP)

**CHOP**

**CD20**

Rituximab  
(R-CHOP)

**CHOP**

**CD20**

Rituximab  
(R-CHOP)

7 cyklov chemoterapie **CHOP**  
Rituximab neschválený (pacient neplatič)

ĎAKUJEM ZA POZORNOST

